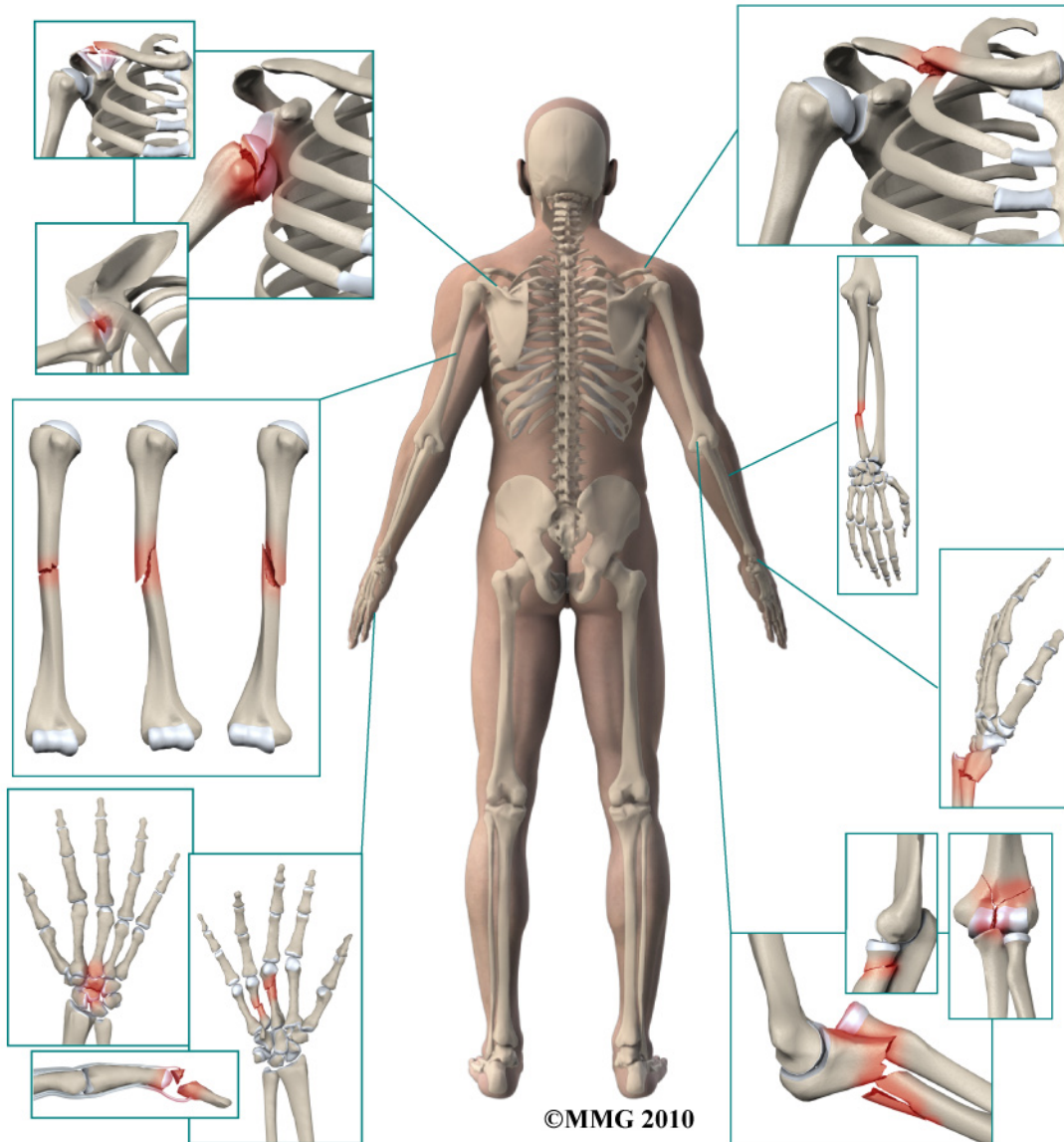


A Patient's Guide to Adult Finger Fractures



©MMG 2010

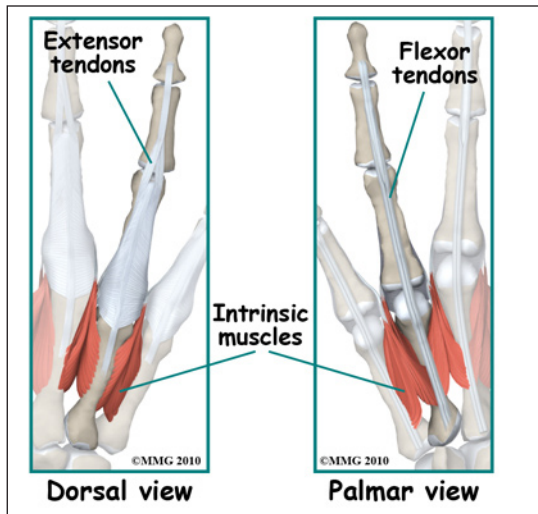
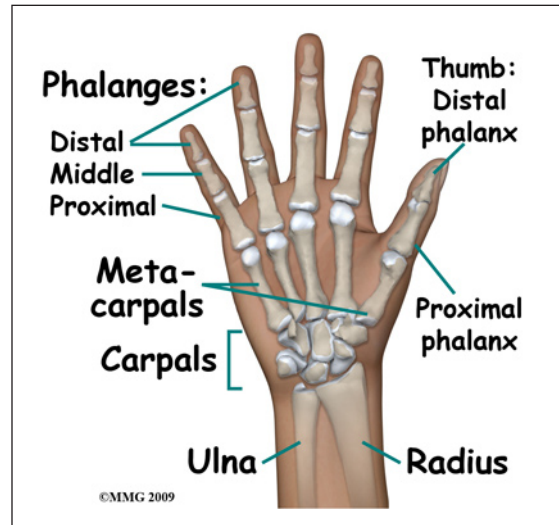
The Central Orthopedic Group



Adult Finger Fractures

Anatomy

The four fingers of the hand each have three bones called *phalanges*: proximal, middle and distal. Each *phalanx* is a short tubular bone. The proximal phalanx is the longest and the distal phalanx is the shortest. Each proximal phalanx forms a joint with the metacarpal bone called the *metacarpophalangeal* (MCP) joint and a joint with the middle phalanx called a *proximal interphalangeal* (PCP) joint. The MCP joints are commonly referred to as the knuckles. There is also a joint between each middle phalanx and each distal phalanx called the *distal interphalangeal* (DIP) joint. Each of these joints is covered with *articular cartilage* a smooth, slippery covering that allows the two bones to glide against one another easily.

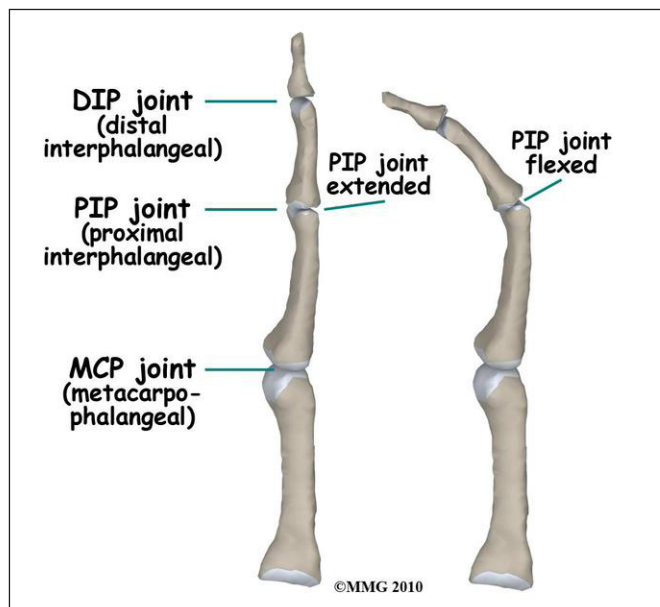


The fingers move because of a very complex arrangement of muscles connected to tendons that attach to different bones of the fingers. Some of these tendons bend the fingers (*flexor tendons*), others straighten the fingers (*extension tendons*) and yet others fine tune and balance the motion of the fingers (*intrinsic* muscles and tendons of the hand). These tendons are important in the treatment of finger fractures because they have a tendency to pull the fragments out of alignment. Your surgeon will consider this when deciding whether the fracture

is stable and whether the fracture can be treated with a splint rather than require surgery.

Signs and Symptoms

Because we use our hands to manipulate our world, fingers commonly get in harm's way. A finger fracture can occur in a multitude of ways, but many injuries occur due to crushing or wrenching the finger away from the palm. There is usually immediate pain and swelling in the finger. You may also



see that the finger is deformed. It is common to see a bump over the back of the finger where the fracture is located and angulated (or bent). Many finger fractures also have lacerations or damage to the skin and soft tissues. Motion is painful; you will probably not be able to grip using the hand due to pain.

Evaluation

The primary goal of the clinical evaluation of a finger fracture is to determine the pattern of the fracture. Based on the fracture pattern, your surgeon will need to decide if 1) the fracture is in stable alignment and can be simply protected in special splint until it heals, 2) the fracture pattern can be reduced (or manipulated) to a stable alignment without surgery and held with a splint until it heals or 3) surgery will be necessary to align the fracture fragments and fix the fragments with some combination of metal pins, metal plates and metal screws. The fracture is evaluated by taking several x-rays of the hand and finger. Your surgeon will pay particular attention to fractures that involve the joints: the MCP, PIP, and DIP joints. These fractures can both affect the stability of the joints and damage the joint surface, leading to weakness or continued pain after the fracture heals. These fractures commonly require surgery to repair the joint surface.

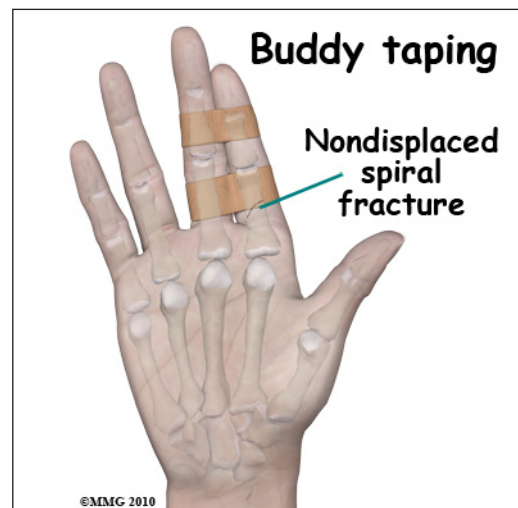Treatment

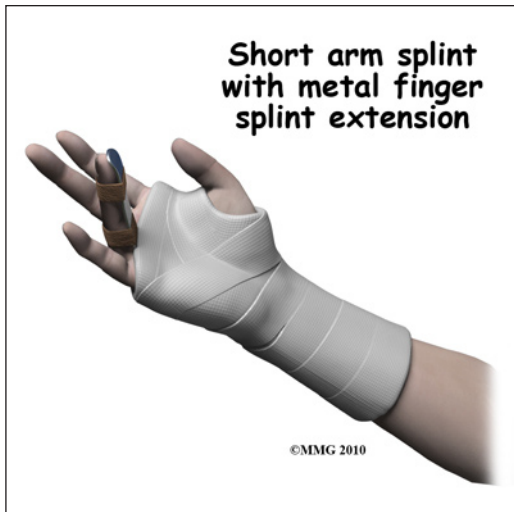Many finger fractures do not require surgery. If the fracture involves one or more joints, surgery may be required to repair the joint. If the fracture is *open* (also called a "compound" fracture), meaning there is a laceration that connects with the fracture, surgery is required to cleanse the fracture fragments and reduce the risk of infection.

Non-Surgical

If your surgeon decides that the fracture can be treated without surgery then buddy taping, a splint or a cast is used until the fracture heals. Buddy taping is used primarily for very stable fractures where the fragments are unlikely to move and displace. Buddy taping simply means that the injured finger is taped to the finger immediately beside the injured finger. The "buddy" finger supports the injured finger protecting it from further injury while helping the injured finger to bend and straighten with assistance from the buddy finger. This motion helps prevent stiffness.

If your surgeon decides that the fragments should be manipulated (or moved) into alignment, then a *closed reduction* will be performed to align the fracture fragments better. To perform a closed reduction, a local anesthetic block is used to numb the area around the fracture. Once the fracture is no longer painful, the surgeon will use a combination of pulling and pushing to align the fracture fragments into an acceptable position. A splint or cast that supports the wrist, hand and several fingers is usually applied. Most fractures of the phalanges heal enough in three or four weeks to remove the rigid splint and begin gentle, protected range of motion. X-rays will be taken





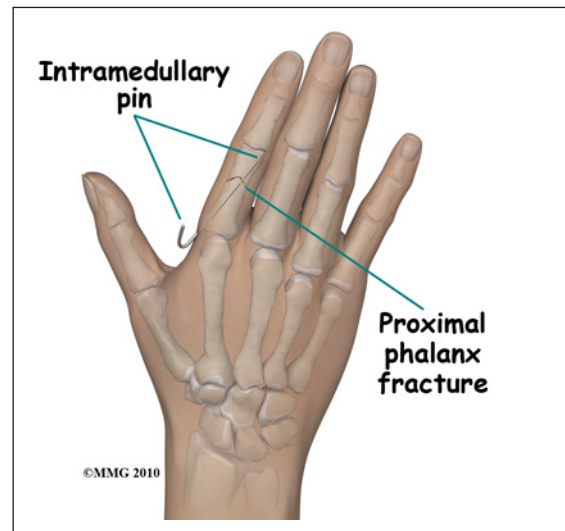
frequently to make sure that the fracture remains in alignment. Once your surgeon thinks that the fracture has healed, the cast or fracture brace are discontinued and you will work with a physical therapist to regain the motion and strength in the hand and fingers.

Surgery

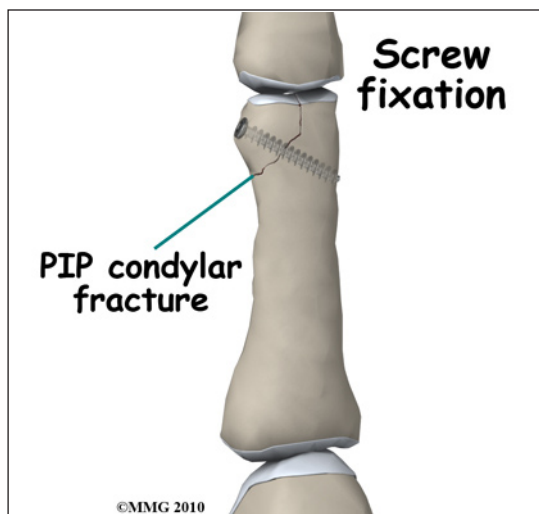
A finger fracture may require surgery. If your surgeon makes the assessment that the fracture will NOT give you good finger function without surgery, surgical treatment will be recommended. If the fracture cannot be held in acceptable position with a splint and the fragments begin to separate, surgery may be suggested after several days or weeks of attempting non-surgical

treatment. Surgical treatment of a finger fracture can be performed in several ways: metal pins placed through the skin and into the fracture fragments to hold them in place or a combination of small metal screws with or without a small metal plate along the side of the bone.

Surgical treatment that ranges from relatively simple to more complex may be considered depending on the fracture pattern. Simple fracture patterns may be treated by placing metal pins through the skin and into the bone fragments to hold the fragments in position as they heal. These pins are inserted while you are in the operating room with the aid of a special X-ray machine



called a *fluoroscope*. The fluoroscope allows the surgeon to see an X-ray image of the bones on a television monitor and guide the placement of the pins by viewing this image. This type of surgery may be done as an outpatient.



Some finger fractures require *Open Reduction and Internal Fixation (ORIF)* using small metal screws or a metal plate and screws. This type of treatment allows the fracture fragments to be restored as close to their normal position as possible and held there until healing occurs. This type of treatment may be necessary to restore the alignment as close as possible. This type of treatment is more likely to be required for fractures that involve the joints of the fingers. ORIF usually requires an incision on the back or side of the finger.

Complications

Stiffness is probably the most common complication of finger fractures. Stiffness can occur quickly even in the uninjured fingers if they are placed in a cast or splint. Your surgeon will want to get your fingers moving as soon as possible.

Nearly all fractures can result in damage to nerves and blood vessels; but this is a rare complication of most finger fractures - unless the injury has occurred due to crushing. The small nerves of the fingers can be damaged or cut as part of the crush injury. Completely severed nerves (and arteries) may need to be repaired surgically.

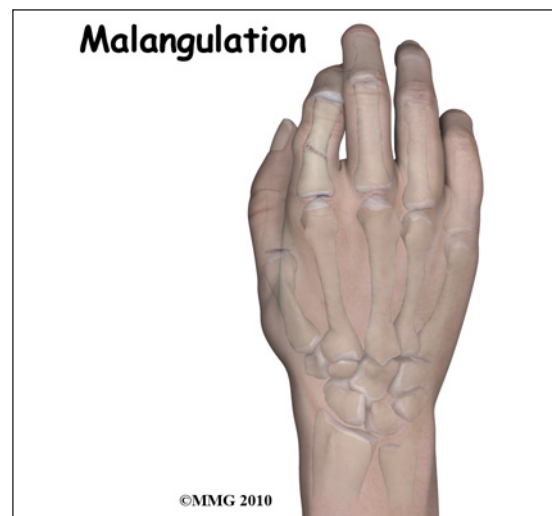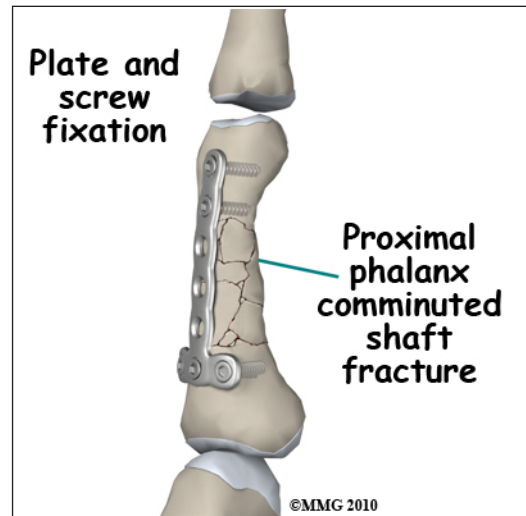
Because finger fractures are sometimes associated with punching someone, lacerations (cuts in the skin) can occur over the knuckles and joints as part of the injury. When these lacerations are caused by human teeth, there is a great risk of serious infection complicating the fracture. This will usually require immediate surgery to cleanse the wound, the knuckle joint and possibly the fracture to reduce the risk of serious infection.

The fracture fragments may fail to heal; this is referred to as a *nonunion*. The fracture fragments may also heal in an unacceptable alignment; this is called *malunion*. If either of these complications occur, the result may be pain, loss of strength and decreased function of the hand and fingers. A second operation may be needed to treat the complication.

Rehabilitation

The prognosis for finger fractures is variable depending on the severity of the injury. Because many finger fractures are crush injuries, it is not uncommon to have the fractures heal with some permanent stiffness in the fingers. Regaining full function may not be possible and it may take several months of rehabilitation with a hand therapist to reach your full potential. The fingers become stiff very fast after being immobilized - whether they are injured or not. Most hand surgeons try to limit the time that the fingers are immobilized and begin physical therapy as soon as possible to prevent stiffness from occurring.

Rehabilitation will begin once your surgeon feels that the fracture is stable enough to begin regaining the range of motion in your wrist, hand and fingers. If surgery has been required, the rehabilitation program will be modified to protect the fixation of the fracture fragments. Your surgeon will communicate with your physical therapist to make sure that your rehabilitation



program does not risk causing the fixation to fail. If the surgeon feels that the fixation is very solid, you may be able progress your program quickly; if the fixation is not so solid, the speed at which you progress may need to be slowed until more healing occurs.

Note: for further information about fractures visit www.eOrthopod.com

Notes